

# Progression of Myopic Maculopathy in Highly Myopic Chinese Eyes

Zhixi Li,<sup>1</sup> Ran Liu,<sup>1,2</sup> Ou Xiao,<sup>1</sup> Xinxing Guo,<sup>1,3</sup> Decai Wang,<sup>1</sup> Jian Zhang,<sup>1</sup> Jason James Ha,<sup>4</sup> Jonathan Tak Loong Lee,<sup>5</sup> Peiying Lee,<sup>5</sup> Monica Jong,<sup>6</sup> Padmaja Sankaridurg,<sup>6</sup> Kyoko Ohno-Matsui,<sup>7</sup> and Mingguang He<sup>1,5</sup>

<sup>1</sup>State Key Laboratory of Ophthalmology, Zhongshan Ophthalmic Center, Sun Yat-sen University, Guangzhou, Guangdong, China

<sup>2</sup>New England College of Optometry, Boston, Massachusetts, United States

<sup>3</sup>Wilmer Eye Institute, Johns Hopkins University, Baltimore, Maryland, United States

<sup>4</sup>Faculty of Medicine, Nursing and Health Sciences, Monash University, Clayton, Australia

<sup>5</sup>Centre for Eye Research Australia, Ophthalmology, Department of Surgery, University of Melbourne, Melbourne, Victoria, Australia

<sup>6</sup>Brien Holden Vision Institute, Sydney, New South Wales, Australia

<sup>7</sup>Department of Ophthalmology and Visual Science, Tokyo Medical and Dental University, Tokyo, Japan

Correspondence: Mingguang He, Stata key Laboratory of Ophthalmology, Zhongshan Ophthalmic Center, Sun Yat-sen University, No. 54 Xianlie Road, Yuexiu District, Guangzhou, Guangdong 510060, People's Republic of China; mingguang.he@unimelb.edu.au.

ZL and RL contributed equally to the work presented here and should therefore be regarded as equivalent authors.

Submitted: September 20, 2018

Accepted: February 19, 2018

Citation: Li Z, Liu R, Xiao O, et al. Progression of myopic maculopathy in highly myopic Chinese eyes. *Invest Ophthalmol Vis Sci.* 2019;60:1096-1104. <https://doi.org/10.1167/iov.18-25800>

**PURPOSE.** To evaluate the 2-year changes in myopic maculopathy and its associations in highly myopic eyes.

**METHODS.** This was a longitudinal, observational cohort study involving 657 Chinese participants with bilateral high myopia ( $\leq -6.00$  diopters spherical power), who were followed for 2 years. The worst eye of each participant was considered for the analysis. Myopic maculopathy was graded based on fundus photographs, using the International Photographic Classification and Grading System for Myopic Maculopathy.

**RESULTS.** The mean baseline age was  $21.6 \pm 12.2$  years (range, 6.8-69.7 years). Myopic maculopathy progressed in 97 (14.8%) of 657 eyes, of which 24 eyes progressed to a higher category of myopic maculopathy, including from no maculopathy to tessellated fundus in 17 eyes, from tessellated fundus to diffuse atrophy in 6 eyes, and from diffuse to patchy atrophy in 1 eye. Among 122 lesion changes identified, the most common changes were enlargement of diffuse atrophy ( $n = 50$ , 41.0%), appearance of lacquer cracks ( $n = 28$ , 23.0%), enlargement of patchy atrophy ( $n = 10$ , 8.2%) and development of additional lacquer cracks ( $n = 7$ , 5.8%). In addition, we identified 1 eye with enlargement of a Fuch's spot, and 1 eye with active choroidal neovascularization. In multiple logistic regression analysis, myopic maculopathy progression was associated with older age, longer axial length, greater change in myopic spherical equivalent and more severe myopic maculopathy at baseline.

**CONCLUSIONS.** Myopic maculopathy progressed in approximately 15% of highly myopic eyes over a 2-year period. Further studies with longer follow up periods are required to confirm identified risk factors for progression.

**Keywords:** high myopia, myopic maculopathy, progression

The reported prevalence of high myopia in adults ranges from 1.6% to 4.6% in Western countries and 0.8% to 9.1% in Asian countries.<sup>1-7</sup> Myopic maculopathy is a leading cause of irreversible and usually bilateral visual impairment among individuals of working age, especially in East Asian populations.<sup>8-12</sup>

Myopic maculopathy refers to a range of chorioretinal lesions that develop secondary to myopia. Due to a lack of consensus on the definition of myopic maculopathy proposed in various studies,<sup>13-16</sup> it is difficult to compare the results of relevant studies. To address this limitation, a classification on severity of myopic maculopathy has been suggested<sup>17</sup> and used in some studies.<sup>18-21</sup> However, some related clinical modalities are difficult to be categorized using this classification system due to the lack of longitudinal observations and consequently, a poor understanding of the natural history of the disease.<sup>22</sup> In 2015, Ohno-Matsui et al.<sup>23</sup> proposed the International Photographic Classification and Grading System for Myopic Macu-

lopthy to determine the presence and/or rate the severity of this condition based on clinical observations of myopic maculopathy cases,<sup>22</sup> thus providing a universally accepted method of assessment of myopic maculopathy for relevant clinical and epidemiological studies. In this study, we adopted this classification to evaluate myopic maculopathy.

Despite the clinical significance of myopic maculopathy and its contribution to the burden of irreversible bilateral vision loss,<sup>24,25</sup> the progression of changes in myopic maculopathy has not been well documented, especially within highly myopic eyes. In 1982, Curtin et al.<sup>26</sup> reported that 35% of 102 eyes with staphylomata progressed to more severe stage of the condition after 5 years. Ohno-Matsui et al.<sup>27</sup> examined 66 eyes with lacquer cracks (LC) and found that 22.2% developed additional LC and 38.0% developed choroidal neovascularization or atrophic changes over a 6-year period. In addition, the Blue Mountains Eye Study reported that in 46 eyes of older adults ( $\geq 49$  years old) with myopic retinopathy, 8.7% developed new



or additional LC and 15.2% developed new or area enlargement of preexisting chorioretinal atrophy after 5 years.<sup>13</sup> However, these observations were from small samples of highly myopic cases recruited mostly from retinal clinics and thus may have resulted in a selection bias.

Thus, the purpose of this study was to evaluate the progression of myopic maculopathy in a large highly myopic Chinese cohort and identify related risk factors and clinical characteristics.

## METHODS

### Study Participants

The study participants were enrolled from the Zhongshan Ophthalmic Center-Brien Holden Vision Institute (ZOC-BHVI) High Myopia Cohort Study. The study methodology has been described in detail elsewhere.<sup>28</sup> In brief, participants aged 7 to 70 years with high myopia, defined as  $-6.00$  diopters (D; expressed as spherical power) or greater in both eyes, were enrolled, after excluding eyes with myopia secondary to other eye diseases and/or systemic diseases, ocular surgery and any severe systemic diseases. A baseline examination was performed on 884 participants between November 2011 and October 2012. Of these participants, 657 (74.3%) participated in the follow-up visit (2013–2015) and the remaining 227 (25.7%) either declined or were lost to follow-up.

The study adhered to the tenets of the Declaration of Helsinki and approval was obtained from the Institutional Review Board of Zhongshan Ophthalmic Center. Written informed consent was obtained from all participants.

### Examinations

All participants received a comprehensive eye examination for both eyes. Before cycloplegia, axial length (AL) was measured using either an optical low-coherence reflectometry (Lenstar LS-900; Haag-Streit AG, Gartenstadtstrasse, Koeniz, Switzerland) or a partial coherence interferometry (IOLMaster; Carl Zeiss Meditec, Oberkochen, Germany) if the AL exceeded the range of Lenstar measurement (32 mm). After complete bilateral cycloplegia (Mydrin-P, 0.5% tropicamide+0.5% phenylephrine, 2 drops; 5 minutes apart), refractive error was measured using an autorefractor (Topcon KR-8800; Topcon Corp., Tokyo, Japan). Best corrected visual acuity (BCVA) was recorded using a LogMAR Tumbling E chart (Precision Vision, La Salle, IL, USA). Colored fundus images were obtained using a digital fundus camera (Canon CX-1; Tokyo, Japan). Detailed fundus examination was conducted using three-mirror contact lens by an ophthalmologist (RL).

### Fundus Color Photograph Grading

Two 45° fundus photographs, one centered on the macula and the other centered on the optic disc, were acquired for each fully dilated eye. The presence of myopic maculopathy was determined based on the grading of the fundus photographs using the International Photographic Classification and Grading System for Myopic Maculopathy.<sup>23</sup> Myopic maculopathy was graded into one of 5 categories according to its severity: no myopic retinal degenerative lesion (category 0, C0); tessellated fundus only (category 1, C1); diffuse chorioretinal atrophy (category 2, C2); patchy chorioretinal atrophy (category 3, C3); and macular atrophy (category 4, C4). Additional lesions, referred to as “plus” lesions, were also

evaluated. These included lacquer cracks (LC), Fuch’s spot and myopic choroidal neovascularization (CNV).

Fundus photographs were reviewed using an online grading system (<http://v201eyegrader.com>). We localized the lesions based on a standard grid template from the Early Treatment Diabetic Retinopathy Study (ETDRS)<sup>29</sup> (Fig. 1). Specifically, to investigate the relative distribution of lesions to fovea, the macular region was divided into 9 subfields according to the ETDRS grid and the outer circle radius was defined as the distance from the fovea to the temporal boundary of optic disc.

Myopic maculopathy was defined as progressed in the event of:

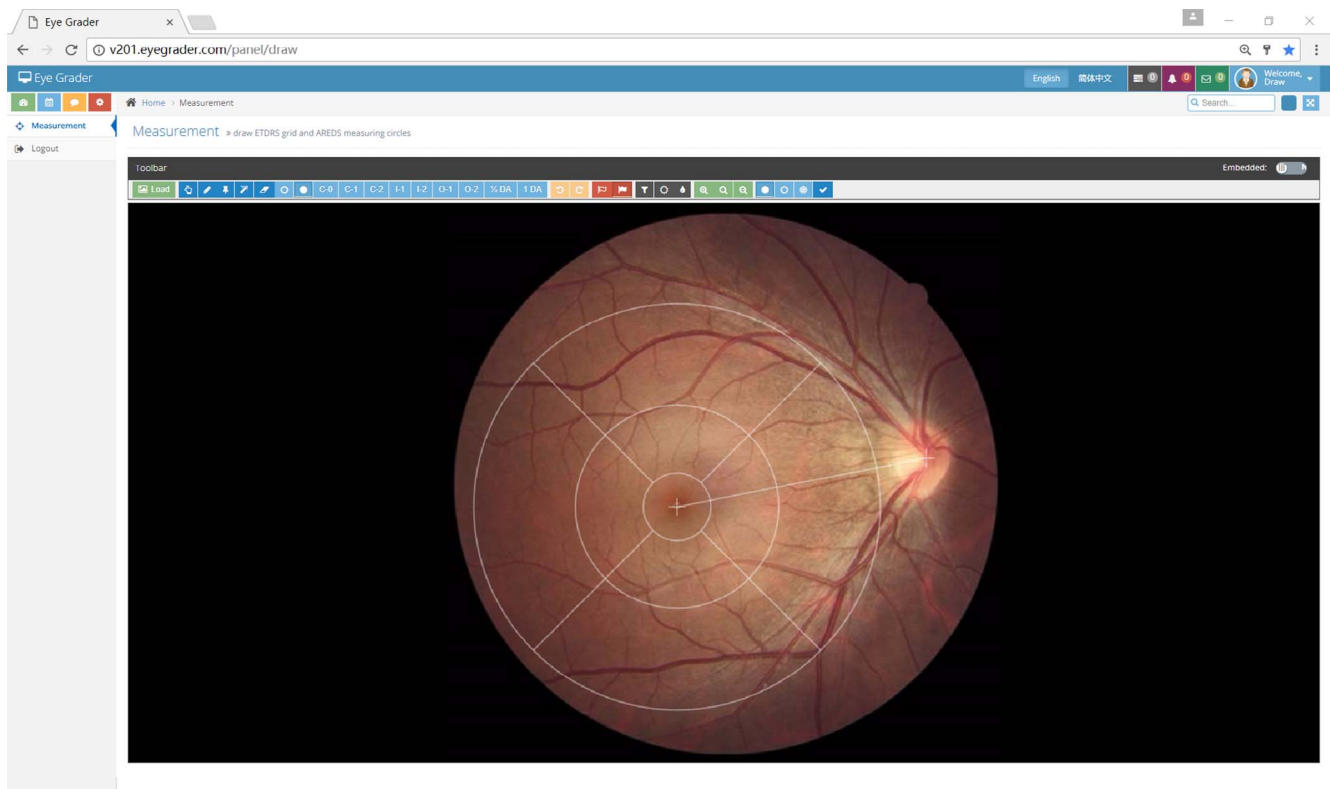
1. For C0 or C1 at baseline, a progression to a higher category or the onset of any “plus” signs;
2. For any category from C2 to C4 at baseline, any one of the following: a progression to a higher category, first appearance of any “plus” signs, or any obvious enlargement of diffuse/patchy chorioretinal atrophy or macular atrophy, which referred to the enlargement of an affected area that could be identified by ophthalmologists when reviewing each participant’s baseline and follow-up photographs side by side;
3. Enlargement of any “plus” signs.

Alternatively, an eye without evident progression was defined as nonprogression. Qualitative analysis was adopted for the comparison of changes, including the development and/or enlargement of lesions, between the baseline and the follow-up visit.

The color fundus photographs were graded by trained ophthalmologists (ZXL, RL, OX, XXG). A conclusive label of each eye was achieved after comparison the grading results of different ophthalmologists at baseline. Before the grading of fundus photographs in the follow-up visit, a subset of fundus photographs (30 participants with 60 eyes, 41 had myopic maculopathy category C2 or greater) selected from baseline was used to test ophthalmologists’ grading accuracy after 2 years by comparing their results with baseline conclusive labels. The median unweighted kappa coefficients were as follows: 0.82 (range, 0.73–0.86) for C0/C1, 0.79 (range, 0.71–0.85) for C2 and more severe myopic maculopathy, 0.65 (range, 0.61–0.75) for LC, and 0.62 (range, 0.60–0.74) for Fuch’s spot. Fundus photographs in follow-up visit were graded side by side with those at baseline to assess the changes of the myopic maculopathy. If there was a disagreement in the grading, the final decision was adjudicated after a panel meeting (ZXL, RL, OX, XXG, MGH).

### Statistical Analysis

All statistical analyses were performed using commercial software (Stata Version 14.0; Stata Corp., College Station, TX, USA). Only one eye of each participant was used for analysis. By default, the worse eye was included. An eye of the participant was categorized as the worse eye based on more severe myopic maculopathy category, or when both eyes had the same severity of myopic maculopathy, the more myopic eye was chosen. Proportions of myopic maculopathy or diffuse chorioretinal atrophy among different age, sex, AL, spherical equivalent (SE), and BCVA groups were compared using Pearson  $\chi^2$  tests. Univariate and multiple logistic regression were used to identify risk factors for myopic maculopathy progression. Odds ratios (OR) with 95% confidence intervals (CIs) were calculated. Given C4 was present in only 4 eyes, they were combined with C3 for analysis. A value of  $P < 0.05$  was considered statistically significant.



**FIGURE 1.** A screenshot of an online grading system adopted in this study, showing the Early Treatment Diabetic Retinopathy Study grading grid superimposed onto the fundus photograph. The grid divides the macular area into nine subfields including central, inner superior, inner nasal, inner inferior, inner temporal, outer superior, outer nasal, outer inferior, and outer temporal.

## RESULTS

A total of 657 (74.3%) of 884 participants at baseline were reexamined after a mean follow-up period of  $2.09 \pm 0.57$  years. These 657 participants had a mean baseline age of  $21.6 \pm 12.2$  years (range, 6.8 to 69.7 years). A total of 349 (53.1%) were female and 308 (46.9%) were male. SE was calculated as the sum of spherical refraction and half of cylindrical power. Mean baseline SE and AL were  $-10.18 \pm 3.38$  D (range,  $-6.00$  to  $-25.63$  D) and  $27.55 \pm 1.56$  mm (range, 23.91 to 34.30 mm), respectively.

### Characteristics in Myopic Maculopathy Progression in High Myopia

A summary of the progression of myopic maculopathy is presented in Figure 2. Of the 657 eyes reexamined, 97 eyes (14.8%) showed myopic maculopathy progression. A total of 24 eyes changed categories to a more severe one. Notably, one eye changed from C2 to C3, with patchy atrophy developing within the original area of diffuse chorioretinal atrophy. Progression from C1 to C2 was observed in six eyes with diffuse chorioretinal atrophy developing at the temporal side to the optic disc. Progression from C0 to C1 was identified in 17 eyes.

A total of 122 lesion changes were identified in the 97 eyes with progressive myopic maculopathy. The most common changes observed was enlargement of diffuse atrophy in 50 eyes, representing 41.0% of the total number of lesions changes. The most frequent “plus” lesion change was the development of LC. ( $n = 28$  eyes, 23.0%). Typical cases are shown in Figure 3. The majority of newly developed LC was observed within the second outermost ring of the ETDRS grid

(shaded region in Fig. 4). The most common location for progression was the inner temporal subfield, followed by the central subfield. Newly developed active CNV was identified in one eye. Enlargements and/or increasing severity of preexisting lesions accounted for 56.6% of all cases of progression in myopic maculopathy.

The proportion of eyes showing myopic maculopathy progression increased with more severe (higher category) baseline myopic maculopathy category (Fig. 5). The proportion of eyes with C2 and more severe myopic maculopathy was higher in the eyes with myopic maculopathy progression compared with those with C0/C1 (46.2% vs. 5.0%,  $P < 0.001$ ).

### Myopic Maculopathy Progression by Age, SE, and AL

Progression of myopic maculopathy was associated with age, AL and SE (Table 1). Myopic maculopathy progression tended to be more common for people older than 40 years of age than any other age group. A higher progression rate was also consistently found in eyes with a higher degree of myopia both at baseline and during the follow-up period as suggested by AL and SE. Figure 6 shows the distribution of non-progression and progression of myopic maculopathy according to age and AL/SE at baseline. In Figure 6A, the proportion of eyes with myopic maculopathy progression in each age group increased as the severity of myopia increased, as indicated by AL (all  $P < 0.05$ ). An age-dependent increase in the proportion of myopic maculopathy progression was also observed, from 8.5% in the 7- to 18-year group to 43.7% in the 40- to 70-year group. The proportion of eyes exhibiting myopic maculopathy progression was also higher in those with longer AL. Similar distributions

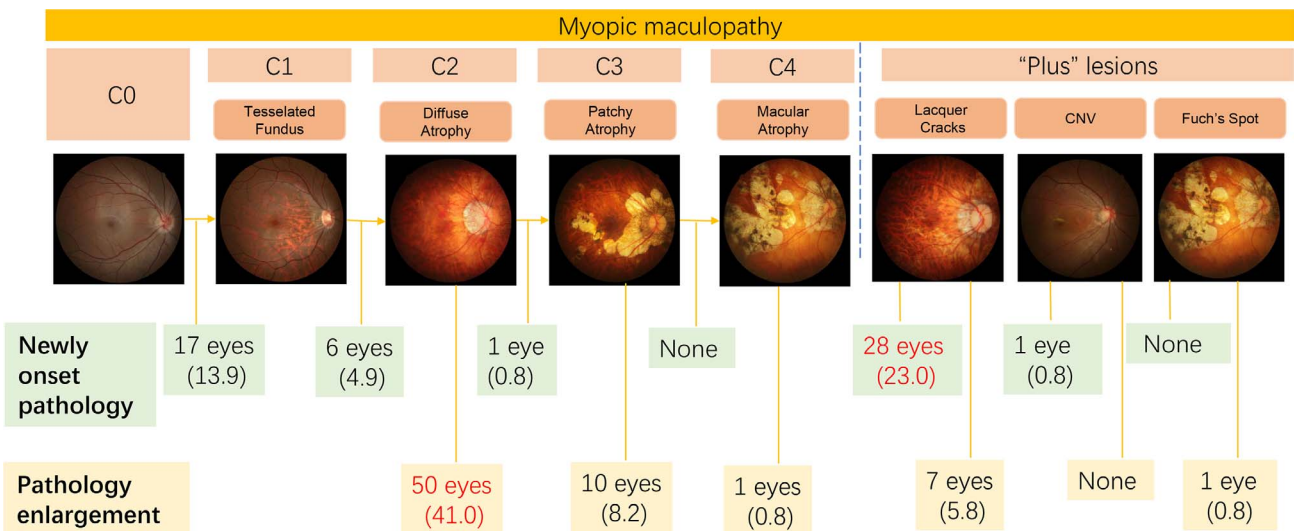


FIGURE 2. The proportion of progressive lesion types among 97 eyes with myopic maculopathy progression in the follow-up period. Percentage is calculated by the number of cases with "new onset" or "enlargement" / the total number of progressive lesions \*100%. Data are presented as *n* (%) unless otherwise indicated. LC, lacquer crack.

were also observed in the proportion of myopic maculopathy progression by baseline SE (Fig. 6B).

Of the 152 eyes with diffuse chorioretinal atrophy at baseline, 50 eyes (32.9%) showed an enlargement of the affected area. Table 2 shows the clinical characteristics of participants with, and without, enlargement of diffuse chorioretinal atrophy. Enlargement of diffuse chorioretinal

atrophy was more prevalent in eyes with longer AL and higher SE. It is noted that eyes with enlargement of diffuse chorioretinal atrophy were more likely to have diffuse atrophy involving the perifoveal area and BCVA less than 20/40 in the follow-up period even though there was no difference in their baseline BCVAs (Table 2).

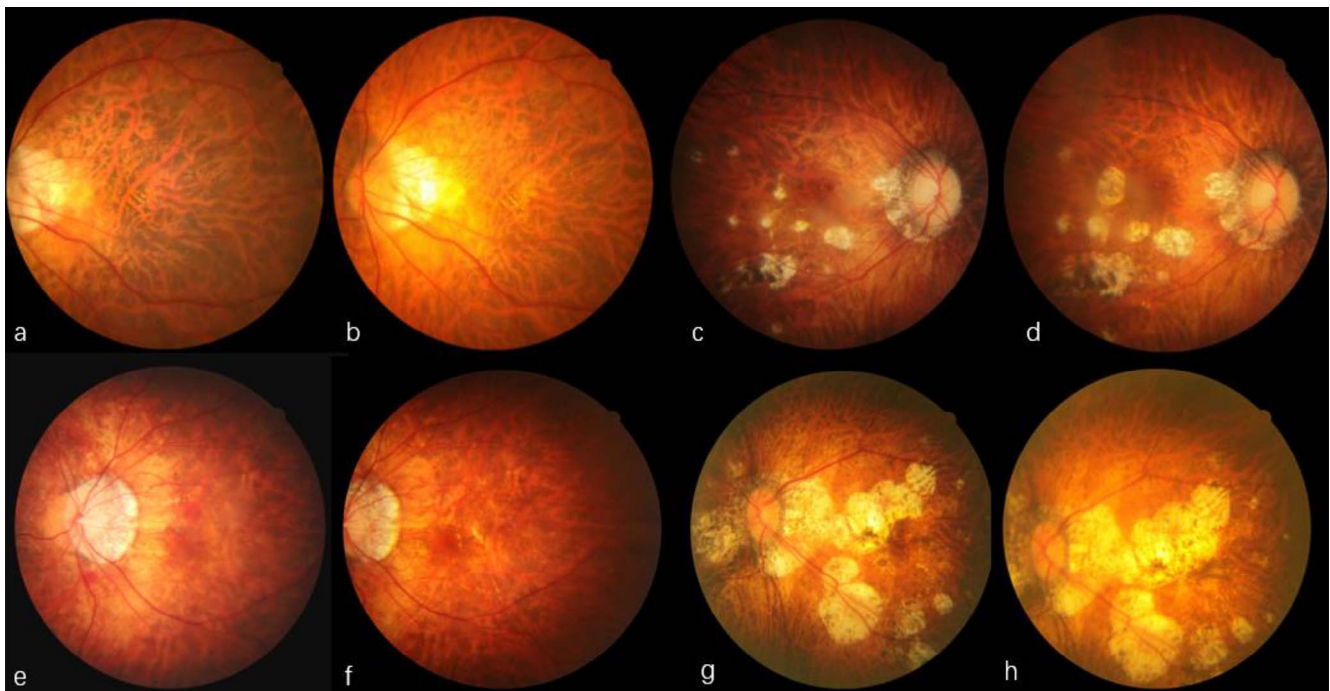


FIGURE 3. Typical cases of myopia maculopathy progression. (a, b) Enlargement of diffuse chorioretinal atrophy. (a) Diffuse chorioretinal atrophy at the temporal side of the optic disc at baseline. (b) Enlargement of diffuse chorioretinal atrophy in the follow-up visit. (c, d) Enlargement of patchy chorioretinal atrophy. (c) Patchy chorioretinal atrophy and lacquer cracks in the macular area. (d) Enlargement of patchy chorioretinal atrophy. (e, f) Development of additional lacquer cracks. (e) Lacquer cracks near the temporal edge of the optic disc and hemorrhage without choroidal neovascularization at baseline. (f) Spontaneously absorption of subretinal hemorrhage and development of additional lacquer cracks in the corresponding area of previous bleeding at the follow-up visit. (g, h) New active choroidal neovascularization. (g) Macular atrophy and fusion of patchy chorioretinal atrophy in the posterior pole. (h) Development of active choroidal neovascularization temporal to the macular atrophy and the enlargement of chorioretinal atrophy area.

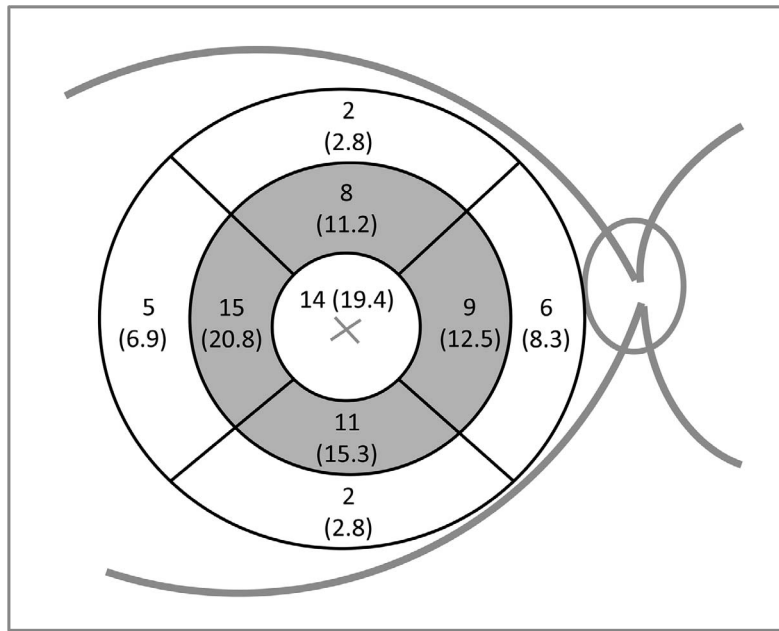


FIGURE 4. The distribution of additional lacquer cracks on an Early Treatment Diabetic Retinopathy Study grid. The shaded region represents the region with the majority of newly developed lacquer cracks.

**Risk Factors for Myopic Maculopathy Progression**

In the multiple regression model, the presence of myopic maculopathy progression was associated with older age, eyes with C2 or greater category of baseline myopic maculopathy and greater AL increase (model 1) / increasing myopic SE (model 2); see Table 3.

In addition, multiple regression analysis showed that the enlargement of diffuse chorioretinal atrophy was more common in people older than 40 years (OR = 5.51; 95% CI

= 1.90-15.95;  $P = 0.002$ ), eyes with greater change in AL (OR 5.15; 95% CI 1.07-24.71;  $P = 0.040$ ), and eyes with greater change in SE (OR = 1.23; 95% CI = 1.02-4.63;  $P = 0.017$ ).

Similarly, we also explored the risk factors for the appearance of LC. Older age (OR 6.49; 95% CI = 2.23-18.85;  $P = 0.001$ ), greater AL change (OR = 1.80; 95% CI = 1.05-3.67;  $P = 0.002$ ), and greater SE change (OR = 1.86; 95% CI = 1.36-2.54;  $P < 0.001$ ) were all predictors of LCs.

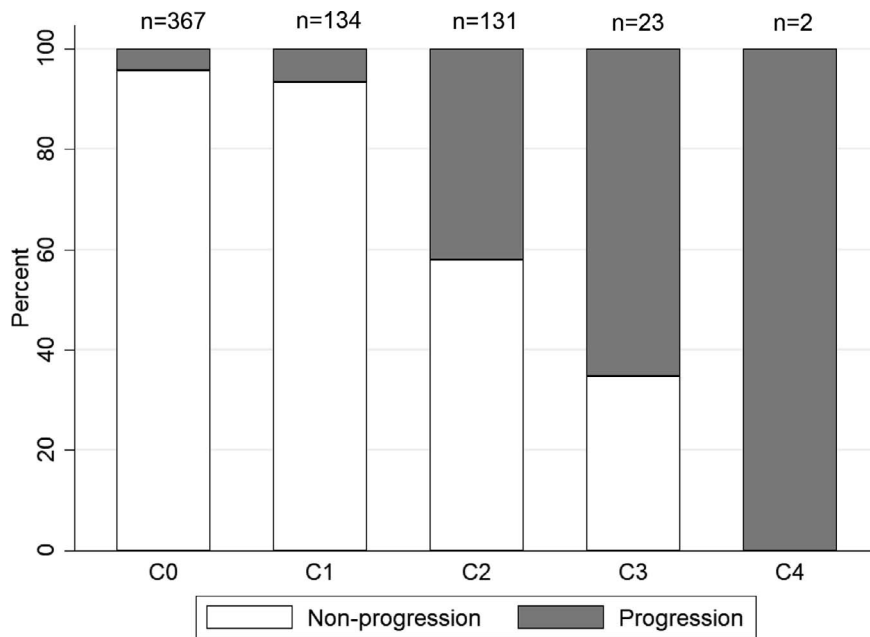


FIGURE 5. Proportion of myopic maculopathy progression by myopic maculopathy category at baseline. Due to the limited sample size, only two eyes were C4 at baseline. One was observed to have enlargement of macular atrophy whereas the other was observed to have enlargement of patchy chorioretinal atrophy.

**TABLE 1.** Clinical Characteristics of Participants With Myopic Maculopathy Progression

	Eyes, <i>n</i>	Myopic Maculopathy		<i>P</i> Value*
		Nonprogression	Progression	
Participants, <i>n</i>	657	560 (85.2)	97 (14.8)	
Age, y				
Total	657	560 (85.2)	97 (14.8)	
7 to 18	390	357 (91.5)	33 (8.5)	
19 to 39	203	167 (82.3)	36 (17.7)	
40 to 70	64	36 (56.3)	28 (43.7)	<0.001
Sex, female/male				
Total	657	560 (85.2)	97 (14.8)	
Female	349	297 (85.1)	52 (14.9)	
Male	308	263 (85.4)	45 (14.6)	0.917
Baseline AL, mm				
Total	654	558 (85.3)	96 (14.7)	
<27.0	263	250 (95.1)	13 (4.9)	
≥27.0 to 29.0	288	256 (88.9)	32 (11.1)	
≥29.0	103	52 (50.5)	51 (49.5)	<0.001
AL in the follow-up, mm				
Total	610	521 (85.4)	89 (14.6)	
<27.0	183	178 (97.3)	5 (2.7)	
≥27.0 to 29.0	317	285 (89.9)	32 (10.1)	
≥29.0	110	58 (52.7)	52 (47.3)	<0.001
Baseline SE, D				
Total	654	560 (85.6)	94 (14.4)	
≤ -6 to -8	173	167 (96.5)	6 (3.5)	
≤ -8 to -10	232	216 (93.1)	16 (6.9)	
≤ -10	249	177 (71.1)	72 (28.9)	<0.001
SE in the follow-up, D				
Total	642	551 (85.8)	91 (14.2)	
≤ -6 to -8	79	77 (97.5)	2 (2.5)	
≤ -8 to -10	208	197 (94.7)	11 (5.3)	
≤ -10	355	277 (78.0)	78 (22.0)	<0.001
BCVA in the baseline				
Total	644	556 (86.3)	88 (13.7)	
≥20/40	586	522 (89.1)	64 (10.9)	
<20/40	58	34 (58.6)	24 (41.4)	<0.001
BCVA decreasing to < 20/40 in the follow-up				
Total	606	529 (87.3)	77 (12.7)	
No	594	523 (88.1)	71 (11.9)	
Yes	12	6 (50.0)	6 (50.0)	<0.001

Data are presented as *n* (%) in each row unless otherwise indicated.  
\* Data are analyzed using Pearson  $\chi^2$  tests.

**DISCUSSION**

To our knowledge, this is the first study to explore myopic maculopathy progression in a large Chinese high myopia cohort using the International Photographic Classification and Grading System for Myopic Maculopathy. Approximately 85.0% of the eyes displayed no progression of myopic maculopathy in the 2-year follow-up period. Among the eyes with progression, enlargement of diffuse atrophy was the most frequently observed change, followed by the appearance of LC. Eyes with more severe myopic maculopathy at baseline were found to have a higher likelihood of progression. Older age, greater

**TABLE 2.** Clinical Characteristics of Participants With Diffuse Chorioretinal Atrophy Enlargement

	Eyes, <i>n</i>	Diffuse Chorioretinal Atrophy		<i>P</i> Value*
		Nonenlargement	Enlargement	
Participants, <i>n</i>	152	102 (67.1)	50 (32.9)	
Age, y				
Total	152	102 (67.1)	50 (32.9)	
7 to 18	62	48 (77.4)	14 (22.6)	
19 to 39	51	33 (64.7)	18 (35.3)	
40 to 70	39	21 (53.9)	18 (46.1)	0.044
Sex, female/male				
Total	152	102 (67.1)	50 (32.9)	
Female	81	58 (71.6)	23 (28.4)	
Male	71	44 (62.0)	27 (38.0)	0.207
Baseline AL, mm				
Total	150	100 (66.7)	50 (33.3)	
<27.0	20	19 (95.0)	1 (5.0)	
≥27.0 to 29.0	50	37 (74.0)	13 (26.0)	
≥29.0	80	44 (55.0)	36 (45.0)	0.001
AL in the follow-up, mm				
Total	137	89 (65.0)	48 (35.0)	
< 27.0	11	11 (100.0)	0 (0.0)	
≥ 27.0 to 29.0	46	37 (80.4)	9 (19.6)	
≥ 29.0	80	41 (51.3)	39 (48.7)	<0.001
Baseline SE, D				
Total	150	101 (67.3)	49 (32.7)	
≤ -6 to -8	5	5 (100.0)	0 (0.0)	
≤ -8 to -10	30	28 (93.3)	2 (6.7)	
≤ -10	115	68 (59.1)	47 (40.9)	0.001
SE in the follow-up, D				
Total	146	100 (69.5)	46 (31.5)	
≤ -6 to -8	3	3 (100.0)	0 (0.0)	
≤ -8 to -10	13	12 (92.3)	1 (7.7)	
≤ -10	130	85 (65.4)	45 (34.6)	0.068
BCVA in the baseline				
Total	143	100 (69.9)	43 (30.0)	
≥ 20/40	107	77 (72.0)	30 (28.0)	
< 20/40	36	23 (63.9)	13 (36.1)	0.361
BCVA in the follow-up				
Total	129	83 (64.3)	46 (35.7)	
≥ 20/40	96	69 (71.9)	27 (28.1)	
< 20/40	33	14 (42.4)	19 (57.6)	0.002
C2 involving the central subfield within ETDRS grid in the follow-up				
Total	152	102 (67.1)	50 (32.9)	
Absent	114	87 (76.3)	27 (23.7)	
Present	38	15 (39.5)	23 (60.5)	

Data are presented as *n* (%) in each row unless otherwise indicated.  
\* Data are analyzed using Pearson  $\chi^2$  tests.

AL elongation, greater SE change, and more severe (C2 or greater) baseline category of myopic maculopathy were predictors for myopic maculopathy progression. Eyes with myopic maculopathy progression showed greater deterioration in BCVA from baseline to follow-up.

To date, very few studies have documented progression of myopic maculopathy using longitudinal data. The Blue Mountains Eye Study reported that myopic maculopathy

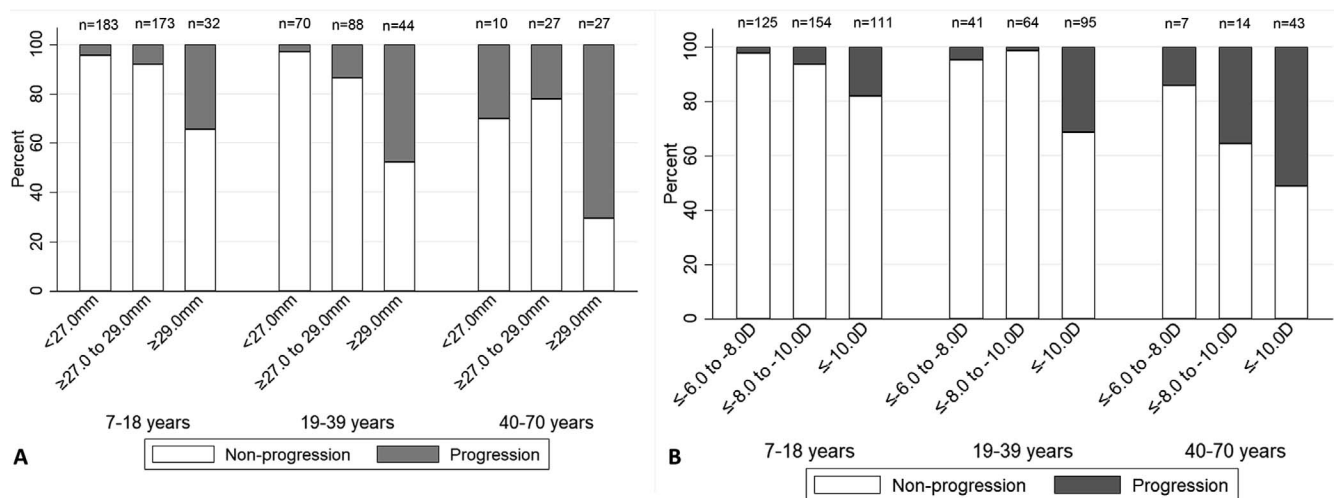


FIGURE 6. Proportion of myopic maculopathy progression by baseline age and axial length or spherical equivalence. (A) proportion of myopic maculopathy progression by baseline age and axial length. (B) proportion of myopic maculopathy progression by baseline age and spherical equivalence.

among eyes of  $\leq -1$  D progressed in 17.4% ( $n = 8$ ) of eyes after 5 years in a small sample of 46 eyes.<sup>13</sup> A further study conducted by Liu et al.<sup>14</sup> found enlargement of chorioretinal atrophy in 17 (9%) eyes with refractive error of  $\leq -0.5$  D, but the overall proportion of eyes that progressed was not presented. However, as these studies did not distinguish between myopia versus high myopia, determination of the progression and characteristics of myopic maculopathy among highly myopic eyes was not possible. Fang et al.<sup>30</sup> investigated myopic maculopathy progression in a hospital-based cohort of Japanese high myopes ( $n = 432$ ) with a refractive error of  $< -8.0$  D or an axial length of  $\geq 26.5$  mm, and found that 58.6% of eyes showed progression over 18 years of follow-up. Differences in the length of the follow-up period and the study population preclude direct comparison of the results of our two studies. Nonetheless, it will be important to extend the period of follow-up for the current cohort to confirm identified risk factors for progression.

Our results indicated that young high myopes were less likely to develop severe myopic maculopathy even with extremely large AL. This may be explained by the fact that

the duration of scleral stretching was not long enough to induce substantial retinal damage.<sup>31-33</sup> In addition, our study showed that age is an important factor for myopic maculopathy progression and therefore we analyzed our data in three age subgroups. The fact that myopic maculopathy develops or progresses disproportionately more common among people aged 40 years and older suggests that the retinal damage secondary to high myopia may require a long time to develop. Both age and axial elongation decrease density of photoreceptors and retinal pigment epithelial cells; the reduction of choroidal thickness in highly myopic eyes may contribute to degeneration and ischemia of outer retina, ultimately causing increased myopic maculopathy progression,<sup>34-38</sup> although all of these speculations require confirmation in further studies.

In our study, myopic maculopathy progression occurred in 4.4% of eyes with C0 and in 6.7% of eyes with C1. For eyes with C2, C3, and C4, the proportions increased to 42.0%, 65.2% and 100%, respectively. These findings were one of the few studies to support the hypothesis that myopic maculopathy tends to progress faster after C1.

TABLE 3. Multiple Logistic Regression to Determine the Correlations Between Variables and Myopic Maculopathy Progression

	N	%	Model 1*			Model 2*		
			Odds Ratio	95% CIs	P	Odds Ratio	95% CIs	P
Baseline age, y								
7 to 18	390	59.4	Reference			Reference		
19 to 39	203	30.9	2.36	1.19-4.68	0.014	1.83	0.98-3.42	0.056
40 to 70	64	9.7	4.21	1.84-9.66	0.001	3.69	1.69-8.03	0.001
Sex								
Male	308	46.9	Reference			Reference		
Female	349	53.1	1.42	0.82-2.45	0.210	1.34	0.79-2.30	0.280
Change in axial length, mm	610	-	3.18	1.34-7.52	0.009	-	-	-
Change in spherical equivalence, D	642	-	-	-	-	1.43	1.11-1.84	0.007
Baseline myopic maculopathy category								
C0	367	55.9	Reference			Reference		
C1	134	20.4	1.08	0.43-2.71	0.864	1.05	0.42-2.62	0.909
C2	131	19.9	12.16	6.25-23.66	<0.001	10.59	5.52-20.31	<0.001
C3/C4	25	3.8	20.18	6.76-60.22	<0.001	17.83	5.89-53.96	<0.001

\* Model 1 included age, sex, change in axial length, and myopic maculopathy categories. Model 2 included age, gender, change in spherical equivalence and myopic maculopathy categories.

Diffuse chorioretinal atrophy enlargement was the most frequently observed progression with a rate of 41%. In comparison, only 24 eyes (19.7%) progressed to a more severe or higher category of myopic maculopathy. These findings suggest the enlargement of preexisting lesions, rather than advancement to a higher myopic maculopathy category, comprises the majority of progression of myopic maculopathy.

We mapped the distribution of appearance of LC using the ETDRS grid. Most LC were located within the second outermost ring of the grid, and LC appeared in the innermost circle in 19.4% of eyes. It is noted that LC or patchy chorioretinal atrophy perifoveally was associated with an increased risk of developing CNV. Hayashi et al.<sup>22</sup> reported that CNV development was observed only in 3.7% of the eyes with diffuse atrophy, whereas it occurred in 20% of eyes with patchy chorioretinal atrophy and in 29.4% of eyes with LC. In the current study, one eye of active CNV developed at the 2-year follow-up (Figs. 3G, 3H), and interestingly, this eye had macular atrophy and fusion of patchy atrophy in the posterior pole area. The area of patchy and macular atrophy was also enlarged and flat, grayish CNV was observed close to the temporal edge of the atrophy.

There are some limitations in our study. Approximately 25.6% (227 of the 884 subjects) declined to continue or were lost to follow-up, which is an inherent problem in any longitudinal epidemiologic study. Those participants who did not complete the study tended to be of older age ( $26.1 \pm 12.6$  years versus  $21.6 \pm 12.2$  years,  $P < 0.001$ ), and had longer AL ( $27.87 \pm 1.77$  mm versus  $27.40 \pm 1.56$  mm,  $P < 0.001$ ) and more C2 or greater myopic maculopathy (31.4% versus 20%,  $P = 0.002$ ) compared with participants who completed follow-up assessment. The differences may lead to potential attrition bias in our assessment. In addition, this study did not report on the change of staphylomata, due to the difficulties of observing such lesions on nonstereoscopic fundus photos.

In conclusion, we have described the progression of myopic maculopathy, and associated clinical characteristics that are observed across a wide range of age groups. To the best of our knowledge, our study is the first to use the International Photographic Classification and Grading System for Myopic Maculopathy to assess progression in a large cohort of Chinese high myopic participants. Characterizing progression of myopic maculopathy will help us better understand the natural history of high myopia. Further studies on longitudinal changes with longer term of follow-up are necessary to develop a comprehensive understanding of the progression, prognosis and natural course of high myopia.

### Acknowledgments

Supported by the Fundamental Research Funds of the State Key Laboratory in Ophthalmology, National Natural Science Foundation of China (81420108008), Science and Technology Planning Project of Guangdong Province in China (2013B20400003) and a grant from the Brien Holden Vision Institute, Australia. Mingguang He receives support from the Research Accelerator Program at the University of Melbourne and the CERA Foundation in Australia. The Centre for Eye Research Australia receives Operational Infrastructure Support from the Victorian State Government in Australia. The sponsor or funding organization had no role in the design or conduct of this research.

Disclosure: Z. Li, None; R. Liu, None; O. Xiao, None; X. Guo, None; D. Wang, None; J. Zhang, None; J.J. Ha, None; J.T.L. Lee, None; P. Lee, None; M. Jong, None; P. Sankaridurg, None; K. Ohno-Matsui, None; M. He, None

### References

- Dandona R, Dandona L, Srinivas M, Giridhar P, McCarty CA, Rao GN. Population-based assessment of refractive error in India: the Andhra Pradesh eye disease study. *Clin Exp Ophthalmol*. 2002;30:84-93.
- Saw SM, Gazzard G, Koh D, et al. Prevalence rates of refractive errors in Sumatra, Indonesia. *Invest Ophthalmol Vis Sci*. 2002;43:3174-3180.
- Bourne RR, Dineen BP, Ali SM, Noorul HD, Johnson GJ. Prevalence of refractive error in Bangladeshi adults: results of the National Blindness and Low Vision Survey of Bangladesh. *Ophthalmology*. 2004;111:1150-1160.
- Xu L, Li J, Cui T, et al. Refractive error in urban and rural adult Chinese in Beijing. *Ophthalmology*. 2005;112:1676-1683.
- Shah SP, Jadoon MZ, Dineen B, et al. Refractive errors in the adult Pakistani population: the national blindness and visual impairment survey. *Ophthalmic Epidemiol*. 2008;15:183-190.
- Kim EC, Morgan IG, Kakizaki H, Kang S, Jee D. Prevalence and risk factors for refractive errors: Korean National Health and Nutrition Examination Survey 2008-2011. *PLoS One*. 2013;8:e80361.
- Pan CW, Zheng YF, Anuar AR, et al. Prevalence of refractive errors in a multiethnic Asian population: the Singapore epidemiology of eye disease study. *Invest Ophthalmol Vis Sci*. 2013;54:2590-2598.
- Wong TY, Loon SC, Saw SM. The epidemiology of age related eye diseases in Asia. *Br J Ophthalmol*. 2006;90:506-511.
- Klaver CC, Wolfs RC, Vingerling JR, Hofman A, de Jong PT. Age-specific prevalence and causes of blindness and visual impairment in an older population: the Rotterdam Study. *Arch Ophthalmol*. 1998;116:653-658.
- Wong TY, Foster PJ, Hee J, et al. Prevalence and risk factors for refractive errors in adult Chinese in Singapore. *Invest Ophthalmol Vis Sci*. 2000;41:2486-2494.
- Liu JH, Cheng CY, Chen SJ, Lee FL. Visual impairment in a Taiwanese population: prevalence, causes, and socioeconomic factors. *Ophthalmic Epidemiol*. 2001;8:339-350.
- Lee JH, Jee D, Kwon JW, Lee WK. Prevalence and risk factors for myopia in a rural Korean population. *Invest Ophthalmol Vis Sci*. 2013;54:5466-5471.
- Vongphanit J, Mitchell P, Wang JJ. Prevalence and progression of myopic retinopathy in an older population. *Ophthalmology*. 2002;109:704-711.
- Liu HH, Xu L, Wang YX, Wang S, You QS, Jonas JB. Prevalence and progression of myopic retinopathy in Chinese adults: the Beijing Eye Study. *Ophthalmology*. 2010;117:1763-1768.
- Curtin BJ, Karlin DB. Axial length measurements and fundus changes of the myopic eye. I. The posterior fundus. *Trans Am Ophthalmol Soc*. 1970;68:312-334.
- Grossniklaus HE, Green WR. Pathologic findings in pathologic myopia. *Retina*. 1992;12:127-133.
- Avila MP, Weiter JJ, Jalkh AE, Trempe CL, Pruett RC, Schepens CL. Natural history of choroidal neovascularization in degenerative myopia. *Ophthalmology*. 1984;91:1573-1581.
- Chen SJ, Cheng CY, Li AF, et al. Prevalence and associated risk factors of myopic maculopathy in elderly Chinese: the Shihpai Eye Study. *Invest Ophthalmol Vis Sci*. 2012;53:4868-4873.
- Shih YF, Ho TC, Hsiao CK, Lin LL. Visual outcomes for high myopic patients with or without myopic maculopathy: a 10 year follow up study. *Br J Ophthalmol*. 2006;90:546-550.
- Chen H, Wen F, Li H, et al. The types and severity of high myopic maculopathy in Chinese patients. *Ophthalmic Physiol Opt*. 2012;32:60-67.



21. Hsiang HW, Ohno-Matsui K, Shimada N, et al. Clinical characteristics of posterior staphyloma in eyes with pathologic myopia. *Am J Ophthalmol*. 2008;146:102-110.
22. Hayashi K, Ohno-Matsui K, Shimada N, et al. Long-term pattern of progression of myopic maculopathy: a natural history study. *Ophthalmology*. 2010;117:1595-1611.
23. Ohno-Matsui K, Kawasaki R, Jonas JB, et al. International photographic classification and grading system for myopic maculopathy. *Am J Ophthalmol*. 2015;159:877-883.
24. Klein RM, Curtin BJ. Lacquer crack lesions in pathologic myopia. *Am J Ophthalmol*. 1975;79:386-392.
25. Chan CC, Benezra D, Rodrigues MM, et al. Immunohistochemistry and electron microscopy of choroidal infiltrates and Dalen-Fuchs nodules in sympathetic ophthalmia. *Ophthalmology*. 1985;92:580-590.
26. Curtin BJ. Posterior staphyloma development in pathologic myopia. *Ann Ophthalmol*. 1982;14:655-658.
27. Ohno-Matsui K, Tokoro T. The progression of lacquer cracks in pathologic myopia. *Retina*. 1996;16:29-37.
28. Chen Y, Xiao O, Guo X, et al. Methodology of the ZOC-BHVI High Myopia Cohort Study: the onset and progression of myopic pathologies and associated risk factors in highly myopic Chinese. *Ophthalmic Epidemiol*. 2018;31-38.
29. Early Treatment Diabetic Retinopathy Study Research Group. Classification of diabetic retinopathy from fluorescein angiograms. ETDRS report number 11. *Ophthalmology*. 1991;98:807-822.
30. Fang Y, Yokoi T, Nagaoka N, et al. progression of myopic maculopathy during 18-year follow-up. *Ophthalmology*. 2018;125:863-877.
31. Kobayashi K, Ohno-Matsui K, Kojima A, et al. Fundus characteristics of high myopia in children. *Jpn J Ophthalmol*. 2005;49:306-311.
32. Samarawickrama C, Mitchell P, Tong L, et al. Myopia-related optic disc and retinal changes in adolescent children from Singapore. *Ophthalmology*. 2011;118:2050-2057.
33. Tong L, Saw SM, Chua WH, et al. Optic disk and retinal characteristics in myopic children. *Am J Ophthalmol*. 2004;138:160-162.
34. Panda-Jonas S, Jonas JB, Jakobczyk-Zmija M. Retinal photoreceptor density decreases with age. *Ophthalmology*. 1995;102:1853-1859.
35. Gao H, Hollyfield JG. Aging of the human retina. Differential loss of neurons and retinal pigment epithelial cells. *Invest Ophthalmol Vis Sci*. 1992;33:1-17.
36. Eriksson U, Alm A. Macular thickness decreases with age in normal eyes: a study on the macular thickness map protocol in the Stratus OCT. *Br J Ophthalmol*. 2009;93:1448-1452.
37. Alamouti B, Funk J. Retinal thickness decreases with age: an OCT study. *Br J Ophthalmol*. 2003;87:899-901.
38. Leng Y, Tam EK, Falavarjani KG, Tsui I. Effect of age and myopia on retinal microvasculature. *Ophthalmic Surg Lasers Imaging Retina*. 2018;49:925-931.