

Presence of Peripheral Neuropathy Is Associated With Progressive Thinning of Retinal Nerve Fiber Layer in Type 1 Diabetes

Cirous Dehghani,¹⁻³ Sangeetha Srinivasan,¹ Katie Edwards,¹ Nicola Pritchard,¹ Anthony W. Russell,⁴ Rayaz A. Malik,^{5,6} and Nathan Efron¹

¹Institute of Health & Biomedical Innovation, and School of Optometry and Vision Science, Queensland University of Technology, Australia

²Commonwealth Scientific and Industrial Research Organisation (CSIRO), Parkville, Victoria, Australia

³Poostchi Eye Research Center, Department of Ophthalmology, School of Medicine, Shiraz University of Medical Sciences, Shiraz, Iran

⁴Department of Diabetes and Endocrinology, Princess Alexandra Hospital, and School of Medicine, University of Queensland, Queensland, Australia

⁵Institute of Cardiovascular Science, University of Manchester, Manchester, United Kingdom

⁶Weill Cornell Medicine - Qatar, Doha, Qatar

Correspondence: Cirous Dehghani, CSIRO Parkville, 343 Royal Parade, Parkville, VIC 3052, Australia; cirous.dehghani@csiro.au.

Submitted: March 5, 2017

Accepted: July 10, 2017

Citation: Dehghani C, Srinivasan S, Edwards K, et al. Presence of peripheral neuropathy is associated with progressive thinning of retinal nerve fiber layer in type 1 diabetes. *Invest Ophthalmol Vis Sci.* 2017;58:BIO234–BIO239. DOI:10.1167/iops.17-21801

PURPOSE. Reduced retinal nerve fiber layer (RNFL) thickness has been demonstrated in patients with diabetic peripheral neuropathy (DPN) in cross-sectional studies. This prospective study defines longitudinal alterations to the RNFL thickness in individuals with type 1 diabetes without (DPN–ve) and with (DPN+ve) DPN and in relation to risk factors for nerve damage.

METHODS. A cohort of 105 individuals with type 1 diabetes (20% DPN+ve) with predominantly mild or no retinopathy and no previous retinal photocoagulation underwent spectral-domain optical coherence tomography (SD-OCT) at baseline, 2 years, and 4 years. SD-OCT scans were acquired at 3.45-mm diameter around the optic nerve head and the overall RNFL and RNFL in the nasal, superior, temporal, and inferior quadrants were quantified. By including serial quantified RNFL parameters, linear mixed models were applied to assess the change in RNFL thickness over time and to explore the associations with other clinical variables.

RESULTS. There was a significant decline in the overall RNFL thickness ($-0.7 \mu\text{m}/\text{y}$, $P = 0.02$) and RNFL in the superior quadrant ($-1.9 \mu\text{m}/\text{y}$, $P < 0.01$) in the DPN+ve group compared with DPN–ve group. The overall RNFL thickness and RNFL in the superior and nasal quadrants were inversely associated with age ($\beta = -0.29$, -0.41 , and -0.29 , respectively; $P \leq 0.02$). Sex, retinopathy, diabetes duration, hemoglobin A_{1c}, lipid profile, blood pressure, cigarette use, alcohol consumption, and body mass index did not show any significant effects ($P > 0.05$).

CONCLUSIONS. Individuals with DPN showed a progressive RNFL thinning overall and in the superior quadrant, which was more pronounced in older individuals. There may be common pathways for retinal and peripheral neurodegeneration that are independent of conventional DPN risk factors.

Keywords: diabetic peripheral neuropathy, optical coherence tomography, retinal nerve fiber layer

The eye is the only site in the body that offers direct in vivo observation of the neural tissue. The corneal nerve network is considered to be a part of the peripheral nervous system, whilst the retina and optic nerve are considered to be a component of the central nervous system (CNS).¹ The corneal subbasal nerve plexus has been studied extensively with in vivo confocal microscopy (IVCCM) and over the past decade it has been established for the early diagnosis and staging of diabetic peripheral neuropathy (DPN).²⁻⁵ Longitudinal studies using IVCCM have also reported the capability of this technique for predicting future incident DPN⁶ and progressive corneal axonal degeneration in patients with DPN.⁷

Retinal tissue, particularly the unmyelinated axons of the ganglion cells that make up the retinal nerve fiber layer (RNFL)

can be imaged with optical coherence tomography (OCT). Further to ophthalmic applications such as assessing the neuronal loss in glaucoma,⁸ OCT has increasingly been implemented for the identification of neuroretinal alterations associated with both central and peripheral aspects of various systemic neurodegenerative disorders. Using OCT, axonal loss evident by thinning of peripapillary RNFL has been identified in multiple sclerosis,⁹ Parkinson's disease,¹⁰ and Alzheimer's disease.¹¹

DPN is a common and potentially debilitating complication of diabetes and its diagnosis relies on traditional measures of neuropathy, which are relatively poor at detecting early nerve damage and identifying those with progression of disease.¹² A few prior cross-sectional studies¹³⁻¹⁵ have investigated the



association of DPN and retinal tissue thickness. While these studies report the RNFL thickness deficits in DPN, to our knowledge no prior longitudinal study has investigated the alterations to this structural parameter of the optic nerve head in relation to DPN. Therefore, this study aimed to define the prospective alterations to the RNFL thickness in individuals with type 1 diabetes (T1DM) without (DPN−ve) and with (DPN+ve) DPN over 4 years and in relation to risk factors for nerve damage.

METHODS

Study Participants

One hundred five participants with T1DM were included at baseline in this prospective longitudinal study. Fifty-two participants were males, and 53 were females; they ranged in age from 14 to 77 years. These participants were enrolled between 2009 and 2010 as a part of the Longitudinal Assessment of Neuropathy in Diabetes Using Novel Ophthalmic Markers (LANDMark) Study¹⁶ from the Diabetes and Endocrinology Research Centre at Princess Alexandra and Mater hospitals and the community in Brisbane, Australia. The research protocol followed the tenets of the Declaration of Helsinki as revised in 2008 and the ethical clearance was obtained from the research ethics committees of Queensland University of Technology, Mater Hospital, and Princess Alexandra Hospital. Written informed consent was obtained from all participants.

Ophthalmic Examinations

All participants underwent ocular screening assessment including slit lamp biomicroscopy, intraocular pressure, and visual acuity. Participants with visual acuity of 20/30 or better, and no history of retinal photocoagulation who had IOP \leq 21 mm Hg and showed no evidence of glaucomatous optic neuropathy were included. Participants were excluded if they had significant media opacity precluding retinal imaging, history of ocular trauma or surgery (except for cataract extraction within 12 months of the visit), or other ocular or systemic diseases and neurologic conditions (such as multiple sclerosis⁹ and Parkinson's disease¹⁰) that might have affected the RNFL.

Spectral-domain OCT (SD-OCT) scanning was conducted with Optovue RTVue (Optovue, Inc., Fremont, CA, USA) on the hand-dominant side of each participant unless the selected eye did not meet the eligibility criteria as stated above. Scans were acquired at 3.45-mm diameter centered at the optic nerve head and the peripapillary RNFL thickness was quantified. According to the manufacturer's user manual, RTVue is capable of acquiring 26,000 scans per second with a resolution of 5 μ m. For the purpose of this study, five structural parameters of interest were obtained including overall RNFL thickness (RNFL_{Overall})—the average of all quadrants—and RNFL thickness in the superior (RNFL_{Sup}), nasal (RNFL_{Nasal}), inferior (RNFL_{Inf}), and temporal (RNFL_{Temp}) quadrants.

Three-field color fundus photography was performed by using a Visucam digital camera (Carl Zeiss Meditec AG, Jena, Germany). To assure consistency in defining the diabetic retinopathy (DR) levels, one ophthalmologist graded the digitally stored retinal images, using the ETDRS scale of diabetic retinopathy severity,¹⁷ in a masked fashion. All ophthalmic assessments were undertaken at baseline and at 2 years and 4 years, using the same devices.

Demographic and Metabolic Parameters

Demographic and general health information including age, diabetes duration, tobacco use, and alcohol consumption were collected. All participants underwent annual assessment of body mass index (BMI), blood pressure, hemoglobin A_{1c} (HbA_{1c}), and lipid profile (total cholesterol, low-density lipoprotein cholesterol, high-density lipoprotein cholesterol, and triglycerides).

Neuropathy Assessment

Nerve conduction studies (peroneal motor nerve conduction velocity [ankle to fibula head] and amplitude [ankle to extensor digitorum brevis], neuropathy disability score [NDS],¹⁸ and diabetic neuropathy symptom score [DNSS])¹⁹ were investigated for all participants at baseline. The presence of DPN was determined by using Toronto criteria²⁰; that is, individuals were considered to have DPN if they had abnormal nerve conduction (compared with age-matched controls in the LANDMark study¹⁶) and a sign (NDS score \geq 3 of 10) or symptom (DNSS \geq 1 of 4) of neuropathy.

Statistical Analysis

The Kolmogorov-Smirnov test was applied to examine the normal distribution of data. Quantitative variables were expressed as the mean \pm SD. To examine the changes to the RNFL parameters over time and their relationship with other variables, five linear mixed models were fitted wherein the obtained serial RNFL parameters (RNFL_{Overall}, RNFL_{Sup}, RNFL_{Nasal}, RNFL_{Inf}, and RNFL_{Temp}) were individually included as dependent variables. Sex and neuropathy status were entered as factors, while age, time of visit, and retinopathy level were specified as time-varying variables. Since information related to alcohol consumption, tobacco usage, blood biochemistry, BMI, and blood pressure was collected annually, the average of these parameters over five visits in addition to diabetes duration were also included as predictor variables in the individual models. The IBM SPSS Statistics 21 (SPSS, Inc., Chicago, IL, USA) was used to analyze the data and a *P* value $<$ 0.05 was considered statistically significant.

RESULTS

Table 1 shows the baseline demographic and clinical data of the participants enrolled in this study. Using the ETDRS grading scale, 61% had no apparent DR (ETDRS score = 10) and 36% had mild retinopathy (ETDRS score = 20–35). Two participants had moderate nonproliferative (ETDRS score = 43) and one had mild proliferative (ETDRS score = 61) retinopathy. When stratified according to the Toronto criteria, 21 participants (20%) had DPN (DPN+ve). Compared to those without DPN (DPN−ve), participants with DPN (DPN+ve) were older, had longer diabetes duration and higher systolic blood pressure (Table 1). While overall RNFL (102.5 vs. 109.5 μ m, *P* = 0.01), RNFL_{Nasal} (72.2 vs. 80.0 μ m, *P* = 0.02), and RNFL_{Inf} (129.5 vs. 139.5 μ m, *P* = 0.02) were significantly reduced in DPN+ve group compared with DPN−ve group at baseline, when analysis was adjusted for age, none of the RNFL parameters differed significantly between the two groups (*P* $>$ 0.15).

Comparison of baseline and year-4 data in the entire cohort showed that there was a slight but statistically significant worsening of neuropathy severity (NDS score, 1.1 \pm 1.8 vs. 1.5 \pm 2.4, *P* $<$ 0.05). Over 4 years, 65 participants showed stable DR, while 25 participants either developed DR (*n* = 9) or showed progression (*n* = 16). Of these 25 participants, the step of DR worsening/the number of participants was recorded as

TABLE 1. Demographics, Clinical Characteristics, and Neuropathy Measures of the Participants at Baseline

Parameter	Total (n = 105)	DPN-ve (n = 21)	DPN+ve (n = 84)	P Value (DPN-ve vs. DPN+ve)
Age, y	45 ± 15	42 ± 15	56 ± 10	<0.01*
Diabetes duration, y	13.0 (24.0)	10.0 (19.0)	33.5 (26.5)	<0.01†
Retinopathy level, ETDRS	10.0 (10.0)	10.0 (10.0)	15.0 (25.0)	0.18†
HbA _{1c} , %	8.0 ± 1.3	7.9 ± 1.3	7.9 ± 1.2	0.84*
Total cholesterol, mM	4.7 ± 0.9	4.7 ± 0.9	4.7 ± 1.1	0.97*
HDL cholesterol, mM	1.5 ± 0.4	1.5 ± 0.4	1.6 ± 0.4	0.50*
Triglycerides, mM	0.8 (0.5)	0.9 (0.5)	0.8 (0.7)	0.66†
LDL cholesterol, mM	2.7 ± 0.8	2.7 ± 0.8	2.6 ± 0.9	0.45*
Cigarettes, No./d	1.1 ± 3.7	1.2 ± 3.5	1.0 ± 4.4	0.38†
Alcohol, units/wk	3.8 (7.0)	3.0 (7.0)	4.0 (8.0)	0.34†
BP systolic, mm Hg	120 ± 14	118 ± 14	127 ± 14	0.01*
BP diastolic, mm Hg	73 ± 8	73 ± 7	73 ± 9	0.75*
BMI, kg/m ²	26.6 ± 4.7	26.4 ± 4.5	27.2 ± 5.7	0.50*
Neuropathy disability score, 0-10	0.0 (1.0)	0.0 (1.0)	3.0 (3.0)	<0.01†
Diabetic neuropathy symptom score, 0-4	0.0 (0.0)	0.0 (0.0)	1.0 (2.0)	<0.01†
Peroneal nerve conduction velocity, m/s	45.6 ± 5.8	46.9 ± 5.4	40.5 ± 4.6	<0.01*
Peroneal nerve amplitude, mV	3.8 (4.1)	4.8 (3.9)	2.1 (2.9)	<0.01†

Data presented as mean ± standard deviation, or median (interquartile range) for nonnormally distributed variables. BP, blood pressure; DPN-ve, participants with diabetes and no peripheral neuropathy; DPN+ve, participants with diabetes and peripheral neuropathy; HDL, high-density lipoprotein; LDL, low-density lipoprotein.

* Independent *t*-test.

† Mann-Whitney *U* test.

follows: one step/*n* = 18, two steps/*n* = 5, three steps/*n* = 1, and four steps/*n* = 1. Five participants showed regression in their DR level, all with one-step improvement. Only systolic blood pressure showed a statistically significant but clinically trivial decrease (120 ± 14 vs. 117 ± 11 mm Hg, *P* = 0.02), while other parameters including HbA_{1c}, total cholesterol, BMI, and diastolic blood pressure remained unchanged (*P* > 0.09).

Figure 1 illustrates the longitudinal trends for RNFL thickness over three visits. Table 2 provides a summary of the results of the five mixed model analyses. As can be seen from Table 2, among the included predictors in five mixed models, the association of time × neuropathy status interaction (changes in RNFL thickness parameter in relation to neuropathy status over time) was statistically significant (*P* < 0.05) in two models where RNFL_{Overall} and RNFL_{Sup} were dependent variable ($\beta = -0.69$, *P* = 0.02 and $\beta = -1.90$, *P* = 0.01, respectively). However, this interaction was marginally nonsignificant for RNFL_{Nasal} ($\beta = -1.4$, *P* = 0.05). RNFL_{Overall}, RNFL_{Sup}, and RNFL_{Nasal} were also inversely associated with age ($\beta = -0.29$, -0.41 , and -0.29 , respectively; *P* ≤ 0.02). Figure 2 facilitates better appreciation of the annual rate of alteration in RNFL thickness in the DPN+ve compared to DPN-ve group, while these changes were adjusted for age effect and other variables. Sex, retinopathy level, duration of diabetes, HbA_{1c}, lipid profile, blood pressure, cigarette use, alcohol consumption, and BMI did not show any significant effects (*P* > 0.05).

DISCUSSION

Further to previous cross-sectional studies that have demonstrated an abnormality in the neuroretinal tissue in patients with DPN,^{13-15,21} this 4-year longitudinal study showed that RNFL thickness quantified by using SD-OCT can serve as a potentially useful technique for monitoring axonal loss in patients with DPN. In this cohort of subjects with T1DM and predominantly mild or no retinopathy, the presence of DPN was associated with a significant linear reduction in the peripapillary RNFL measured by OCT. In the DPN+ve group,

the RNFL_{Overall} reduced at an annual rate equal to 0.7 μm/y as compared with DPN-ve individuals.

We further expanded our analysis to explore which optic nerve head quadrant was implicated in the progressive overall thinning associated with DPN. In normal eyes, histologic as well as intravital OCT studies have reported that RNFL is thickest in the inferior quadrant followed by the superior quadrant.^{22,23} We showed that the progressive reduction in RNFL was only statistically significant in the superior quadrant, whereby there was a linear annual thinning rate of approximately 2 μm/y in DPN+ve individuals. The RNFL in the inferior (the thickest) and temporal quadrants showed no statistically significant alterations over 4 years in relation to neuropathy status. Whilst a significantly reduced RNFL in the superior quadrant of the optic nerve head has been demonstrated in individuals with T1DM²⁴ and type 2 diabetes (T2DM),²⁵ they did not evaluate it in relation to DPN status. Although marginally nonsignificant, the RNFL_{Nasal} also exhibited considerable thinning (-1.4 μm/y) in comparison to those without DPN.

Hyperglycemia can induce oxidative stress and accumulation of advanced glycation end products, leading to compromised retinal metabolism and retinal neural and glial tissue apoptosis.²⁶⁻²⁸ Although changes in retinal axonal and blood vessel diameter may also contribute to RNFL thinning demonstrated by OCT, it is primarily attributed to a loss of ganglion cell axons. The progressive decline of the peripapillary ganglion cell axons observed here indicates that assessment of the neuroretinal rim using SD-OCT could be of value in monitoring progression of neurodegeneration in individuals with DPN and could act as an imaging biomarker to assess the preventive effects of existing or new therapies.

Imaging studies of the CNS have revealed that diabetic neuropathy is not limited to the peripheral nerve network and the CNS may also be affected.²⁹ Owing to the close connection and similarity of the retina to the CNS, this may indicate ongoing CNS involvement in DPN. The assessment of retinal ganglion cell axons, using OCT alongside modern techniques of brain imaging, may provide important insights into central neurodegenerative processes associated with DPN.

Progressive RNFL Thinning in Presence of DPN

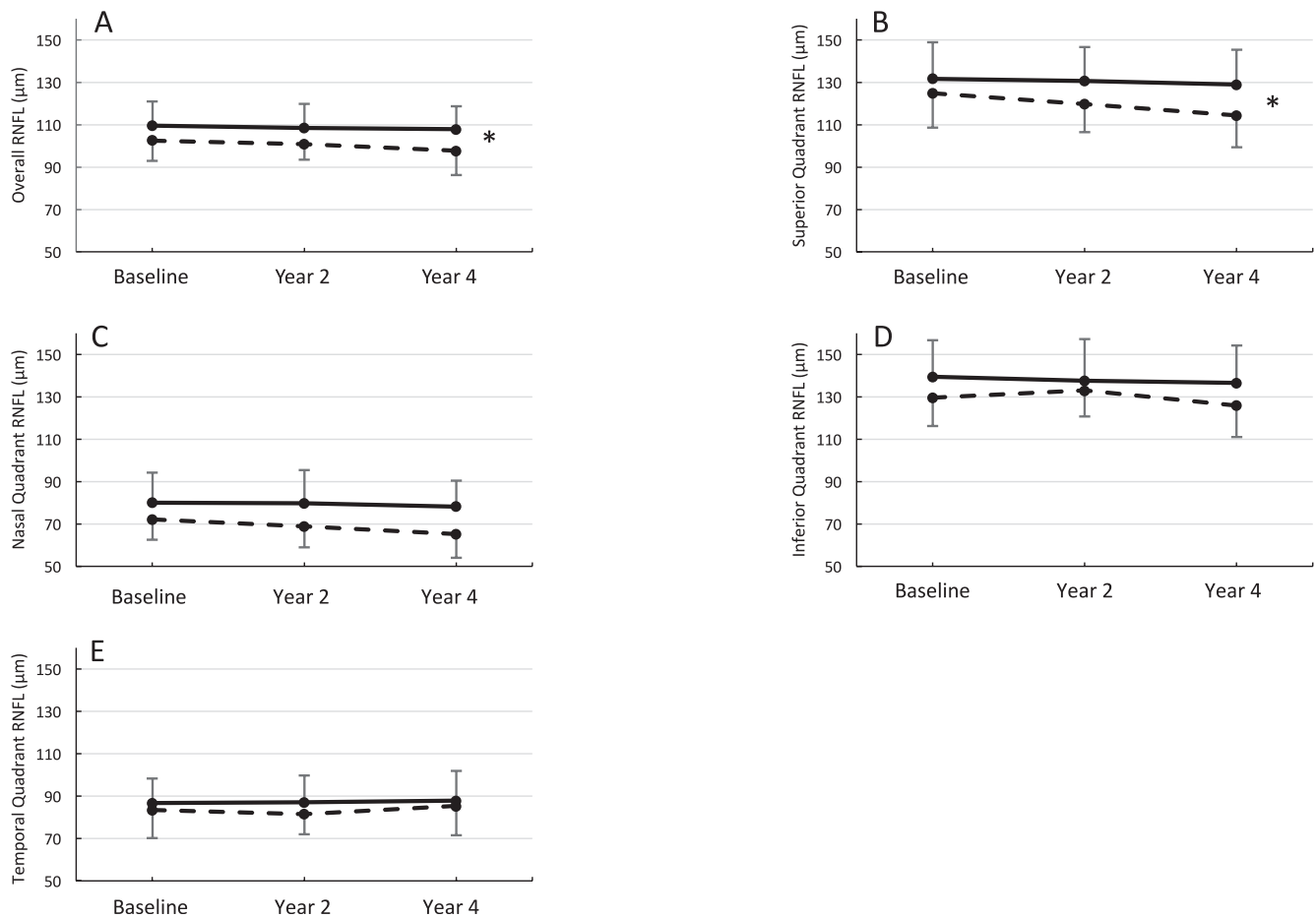


FIGURE 1. Longitudinal course of RNFL: (A) average of all quadrants (overall RNFL), (B) superior quadrant, (C) nasal quadrant, (D) inferior quadrant, and (E) temporal quadrant. On each graph, the *solid line* represents individuals with diabetes without DPN (DPN-ve), and *dashed line* represents those with DPN (DPN+ve). *Asterisks* indicate significantly different trajectories for DPN+ve group compared with DPN-ve group. *Error bars* indicate mean \pm SD.

In the present longitudinal study, several clinical, demographic, and biochemical risk factors for DPN were treated as potential predictors for the change in RNFL, and mixed model techniques were used to control for the potential effects of imbalances in these variables between groups. This analysis showed that in addition to the DPN effect, age was the most important explanatory variable for the change in RNFL in this cohort. For every 10 years of age increase, $\text{RNFL}_{\text{Overall}}$, RNFL_{Sup} , and $\text{RNFL}_{\text{Nasal}}$ declined 3, 4, and 3 μm , respectively. This overall RNFL thinning in patients with diabetes (3 μm per decade) is 50% greater than the extent reported with normal ageing (2 μm per decade).³⁰ This highlights the accelerated age-dependent axon loss of the retinal ganglion cells in diabetes and the importance of taking this variable into account when evaluating patients for diagnosis and follow-up of DPN.

Although several risk factors, in particular glycemic control,²⁷ have been related to the development and progression of diabetic complications, we did not observe any significant relationship between these factors and changes in RNFL thickness in participants with T1DM. This is consistent with the findings of Salvi et al.¹⁵ who reported no significant association of these parameters with average RNFL in T2DM. Moreover, the relatively small changes in RNFL can be attributed to the near optimal control of HbA_{1c} and good management of blood pressure and lipids in our cohort over the follow-up period.

While retinopathy has long been considered as one of the earliest diabetic microvascular complications, there has been some debate as to whether retinal microangiopathy is a secondary effect of underlying neural and glial abnormalities associated with DPN.^{13,15,24,28} Interestingly, in this study, while RNFL thickness reduction was related to the presence of DPN, retinopathy level was not found to be associated with RNFL alterations. Although it is likely that subclinical microvascular changes not detectable by conventional fundus photography may still have contributed in part, this finding contrasts the notion that retinal neurodegeneration is mediated via microvascular mechanisms or is a critical component of diabetic retinopathy.³¹ Nevertheless, this may imply that RNFL thinning or loss of the retinal neuronal tissue is not a primary effect of vascular changes associated with diabetic retinopathy, and supports the reported DPN-related RNFL deficit and its independence from diabetic retinopathy.¹³⁻¹⁵

A strength of our study was the incorporation of several important risk factors for nerve damage and the employment of a robust linear mixed model analysis that allowed the temporal relationship between changes in RNFL thickness and other important variables (such as age and diabetic retinopathy) to be investigated at both the group and the individual level. Since in this study RNFL thickness was repeatedly measured in the same participants, possible confounding effects of individual differences such as disc size, variation in

TABLE 2. Results of Parameter Estimates and Their Significance Pertaining to Five Linear Mixed Model Analyses Where Overall RNFL and RNFL in Superior, Nasal, Inferior and Temporal Quadrants Were Individually Included as Response Variables

Parameter	Dependent Variable: RNFL _{Overall}		Dependent Variable: RNFL _{Sup}		Dependent Variable: RNFL _{Nasal}		Dependent Variable: RNFL _{Inf}		Dependent Variable: RNFL _{Temp}	
	Estimate	P Value	Estimate	P Value	Estimate	P Value	Estimate	P Value	Estimate	P Value
Sex										
Male	-1.72	0.51	-3.85	0.29	-2.87	0.37	0.60	0.89	-0.27	0.93
Female	0*	-	0*	-	0*	-	0*	-	0*	-
Neuropathy status										
DPN+ve	-1.97	0.54	-0.02	0.99	-5.27	0.19	-2.70	0.61	1.67	0.66
DPN-ve	0*	-	0*	-	0*	-	0*	-	0*	-
Time, y	-0.03	0.85	-0.11	0.74	-0.06	0.86	-0.51	0.13	0.50	0.08
Time × neuropathy interaction										
Time × DPN+ve	-0.69	0.02	-1.90	0.01	-1.41	0.05	-0.19	0.79	0.51	0.40
Time × DPN-ve	0*	-	0*	-	0*	-	0*	-	0*	-
Diabetes duration	0.06	0.53	0.18	0.22	0.03	0.81	-0.04	0.81	-0.03	0.78
Retinopathy level, ETDRS	-0.01	0.77	-0.07	0.45	0.06	0.50	0.12	0.21	0.01	0.92
Age, y	-0.29	0.01	-0.41	<0.01	-0.29	0.02	-0.30	0.07	-0.18	0.12
HbA _{1c} , %	-1.31	0.19	-2.49	0.08	0.12	0.92	-2.01	0.22	-1.25	0.29
Total cholesterol, mM	12.20	0.34	6.61	0.71	17.73	0.25	25.94	0.21	-1.94	0.90
HDL cholesterol, mM	-11.85	0.36	-10.22	0.57	-22.04	0.16	-20.90	0.32	6.74	0.66
Triglycerides, mM	-2.68	0.65	3.21	0.70	-9.66	0.18	-10.31	0.29	5.72	0.41
LDL cholesterol, mM	-11.28	0.38	-5.53	0.75	-17.69	0.25	-25.45	0.22	4.06	0.78
Cigarettes, No./d	-0.15	0.65	-0.45	0.34	-0.35	0.40	0.16	0.77	-0.14	0.73
Alcohol, units/wk	0.34	0.66	1.28	0.23	0.65	0.49	-0.09	0.94	-0.59	0.51
BP systolic, mm Hg	-0.04	0.81	0.04	0.85	0.14	0.48	-0.21	0.44	-0.15	0.44
BP diastolic, mm Hg	0.14	0.62	0.07	0.85	0.01	0.98	0.28	0.54	0.18	0.58
BMI, kg/m ²	-0.39	0.16	-0.68	0.08	-0.26	0.45	-0.40	0.38	-0.18	0.57

Parameters with statistically significant effect (*P* value < 0.05) are shown in bold.
 * This parameter is set to zero because it serves as the reference for comparison.

the number of RNFL axons, refractive error, and axial length³⁰ were obviated.

In this study, retinopathy grading was performed by using three-field fundus photography. Wider retinal fields (e.g., seven-field fundus photography) can provide more information

about changes in retinal periphery. Therefore, the fundus imaging procedure used here could have confounded the staging of diabetic retinopathy and hence could be a potential limitation of this study. Another limitation of this study was that we did not exclude those participants who may have developed neuropathy at later stages from DPN-ve group. Given the nonsignificant cross-sectional effect of DPN we observed at baseline, the possible effect of newly developed DPN would have been negligible.

In this longitudinal study, we only evaluated the RNFL thickness in T1DM. Owing to differences in the pathophysiological mechanisms underlying two main types of diabetes, these findings may not be generalized to T2DM. Previously published reports also indicate that DPN is associated with reduced retinal thickness in the perifovea and parafoveal zones as well as ganglion cell complex^{14,15}; therefore, future studies can focus on these structural parameters and explore which retinal layer is more susceptible to damage by presence of DPN. Given that the structural changes of optic nerve precede visual field defects, future studies may clarify the retinal structure-function relationship in the presence of DPN.

To our knowledge, this is the first longitudinal quantitative report showing accelerated loss of RNFL in patients with T1DM and DPN. This adds to the utility of SD-OCT as a means to track progressive neuronal loss in individuals with diabetes and DPN. This technique may therefore be used as an adjunct to more conventional methods of monitoring the progression of DPN. Furthermore, there may be common and differing risk factors for retinal and peripheral neurodegeneration that merit further study.

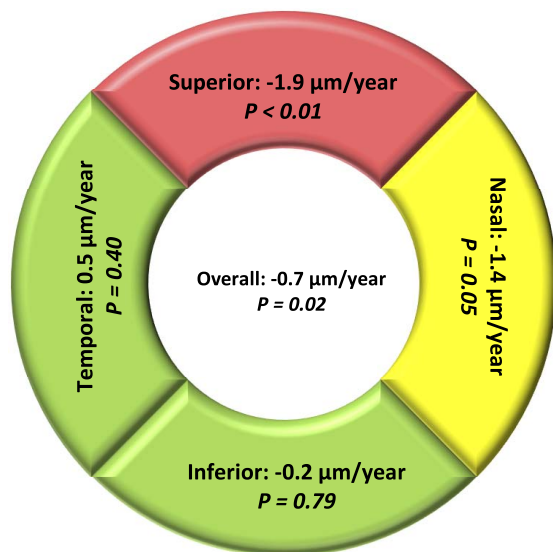


FIGURE 2. Annual rate of change (μm/y) in RNFL thickness in individuals with diabetes and DPN, compared with those without DPN, over 4 years in this study

Acknowledgments

Supported by a Grant from the Juvenile Diabetes Research Foundation International (JDRFI) (8-2008-362).

Disclosure: **C. Dehghani**, None; **S. Srinivasan**, None; **K. Edwards**, None; **N. Pritchard**, None; **A.W. Russell**, None; **R.A. Malik**, None; **N. Efron**, None

References

- Levin AL. Optic nerve. In: Kaufman PL, Alm A, eds. *Adler's Physiology of the Eye: Clinical Application*. 10th ed. St. Louis: Mosby; 2003:603–638.
- Petropoulos IN, Alam U, Fadavi H, et al. Corneal nerve loss detected with corneal confocal microscopy is symmetrical and related to the severity of diabetic polyneuropathy. *Diabetes Care*. 2013;36:3646–3651.
- Tavakoli M, Quattrini C, Abbott C, et al. Corneal confocal microscopy: a novel noninvasive test to diagnose and stratify the severity of human diabetic neuropathy. *Diabetes Care*. 2010;33:1792–1797.
- Petropoulos IN, Alam U, Fadavi H, et al. Rapid automated diagnosis of diabetic peripheral neuropathy with in vivo corneal confocal microscopy. *Invest Ophthalmol Vis Sci*. 2014;55:2071–2078.
- Asghar O, Petropoulos IN, Alam U, et al. Corneal confocal microscopy detects neuropathy in subjects with impaired glucose tolerance. *Diabetes Care*. 2014;37:2643–2646.
- Pritchard N, Edwards K, Russell AW, Perkins BA, Malik RA, Efron N. Corneal confocal microscopy predicts 4-year incident peripheral neuropathy in type 1 diabetes. *Diabetes Care*. 2015;38:671–675.
- Dehghani C, Pritchard N, Edwards K, et al. Natural history of corneal nerve morphology in mild neuropathy associated with type 1 diabetes: development of a potential measure of diabetic peripheral neuropathy. *Invest Ophthalmol Vis Sci*. 2014;55:7982–7990.
- Bussel II, Wollstein G, Schuman JS. OCT for glaucoma diagnosis, screening and detection of glaucoma progression. *Br J Ophthalmol*. 2014;98:ii15.
- Petzold A, de Boer JF, Schippling S, et al. Optical coherence tomography in multiple sclerosis: a systematic review and meta-analysis. *Lancet Neurol*. 2010;9:921–932.
- Yu J-G, Feng YF, Xiang Y, et al. Retinal nerve fiber layer thickness changes in Parkinson disease: a meta-analysis. *PLoS One*. 2014;9:e85718.
- Thomson KL, Yeo JM, Waddell B, Cameron JR, Pal S. A systematic review and meta-analysis of retinal nerve fiber layer change in dementia, using optical coherence tomography. *Alzheimers Dement*. 2015;1:136–143.
- Malik RA. Which test for diagnosing early human diabetic neuropathy? *Diabetes*. 2014;63:2206–2208.
- Shahidi AM, Sampson GP, Pritchard N, et al. Retinal nerve fibre layer thinning associated with diabetic peripheral neuropathy. *Diabet Med*. 2012;29:e106–e111.
- Srinivasan S, Pritchard N, Vagenas D, et al. Retinal tissue thickness is reduced in diabetic peripheral neuropathy. *Curr Eye Res*. 2016;41:1359–1366.
- Salvi L, Plateroti P, Balducci S, et al. Abnormalities of retinal ganglion cell complex at optical coherence tomography in patients with type 2 diabetes: a sign of diabetic polyneuropathy, not retinopathy. *J Diabetes Complications*. 2016;30:469–476.
- Pritchard N, Edwards K, Dehghani C, et al. Longitudinal assessment of neuropathy in type 1 diabetes using novel ophthalmic markers (LANDMark): study design and baseline characteristics. *Diabetes Res Clin Pract*. 2014;104:248–256.
- Davis MD, Fisher MR, Gangnon RE, et al. Risk factors for high-risk proliferative diabetic retinopathy and severe visual loss: Early Treatment Diabetic Retinopathy Study Report #18. *Invest Ophthalmol Vis Sci*. 1998;39:233–252.
- Young MJ, Boulton AJM, Macleod AF, Williams DRR, Sonksen PH. A multicenter study of the prevalence of diabetic peripheral neuropathy in the United Kingdom hospital clinic population. *Diabetologia*. 1993;36:150–154.
- Meijer J, Smit A, Sonderer E, Groothoff J, Eisma W, Links T. Symptom scoring systems to diagnose distal polyneuropathy in diabetes: the Diabetic Neuropathy Symptom score. *Diabet Med*. 2002;19:962–965.
- Tesfaye S, Boulton AJM, Dyck PJ, et al. Diabetic neuropathies: update on definitions, diagnostic criteria, estimation of severity, and treatments. *Diabetes Care*. 2010;33:2285–2293.
- Srinivasan S, Pritchard N, Sampson GP, et al. Diagnostic capability of retinal thickness measures in diabetic peripheral neuropathy. *J Optim*. In Press.
- Pradhan ZS, Braganza A, Abraham LM. Does the ISNT Rule apply to the retinal nerve fiber layer? *J Glaucoma*. 2016;25:e1–e4.
- Dichtl A, Jonas JB, Naumann GOH. Retinal nerve fiber layer thickness in human eyes. *Graefes Arch Clin Exp Ophthalmol*. 1999;237:474–479.
- de Faria JL, Russ H, Costa V. Retinal nerve fibre layer loss in patients with type 1 diabetes mellitus without retinopathy. *Br J Ophthalmol*. 2002;86:725–728.
- Sugimoto M, Sasoh M, Ido M, Wakitani Y, Takahashi C, Uji Y. Detection of early diabetic change with optical coherence tomography in type 2 diabetes mellitus patients without retinopathy. *Ophthalmologica*. 2005;219:379–385.
- Brownlee M. Biochemistry and molecular cell biology of diabetic complications. *Nature*. 2001;414:813–820.
- Forbes JM, Cooper ME. Mechanisms of diabetic complications. *Physiol Rev*. 2013;93:137–188.
- Simó R, Hernández C. Neurodegeneration in the diabetic eye: new insights and therapeutic perspectives. *Trends Endocrinol Metab*. 2014;25:23–33.
- Tesfaye S, Selvarajah D. Advances in the epidemiology, pathogenesis and management of diabetic peripheral neuropathy. *Diabetes Metab Res Rev*. 2012;28:8–14.
- Budenz DL, Anderson DR, Varma R, et al. Determinants of normal retinal nerve fiber layer thickness measured by Stratus OCT. *Ophthalmology*. 2007;114:1046–1052.
- Barber AJ. A new view of diabetic retinopathy: a neurodegenerative disease of the eye. *Prog Neuropsychopharmacol Biol Psychiatry*. 2003;27:283–290.